

Management of ovarian cysts in infants

Yan Xue-qiang, Zheng Nan-nan, Yu Lei, Lu Wei, Bian Hong-qiang, Yang Jun, Duan Xu-fei, Qin Xin-ke

Department of Pediatric Surgery of Wuhan Medical and Health Center for Women and Children, Wuhan, China

Background: To discuss the experience of diagnosis and treatment of ovarian cyst in infants. **Materials and Methods:** A retrospective review was conducted on 20 infants who suffered from ovarian cyst. **Results:** There were no dysplasia ovarian was found in children which were preoperatively diagnosed simplex cyst. Within thirteen children preoperatively detected mixed cystic-solid lesion, six cases ovarian cysts disappeared and two cases underwent poor blood supply in the following time. **Conclusion:** Adverse effects for ovarian cyst in infants can be prevented by aggressive surgical intervention. Harmful effects of ovarian cyst can be prevented by positive surgical intervention despite the diagnostic difficulties in children with clinical symptoms of this condition.

Key words: Infants, laparoscopic, ovarian cyst

How to cite this article: Yan XQ, Zheng NN, Yu L, Lu W, Bian HQ, Yang J, Duan XF, Qin XK. Management of ovarian cysts in infants. *J Res Med Sci* 2015;20:1186-90.

INTRODUCTION

As a special group suffering from ovarian cyst, infants often present with distinctiveness in its occurrence, development, and prognosis. Ovarian cyst in infants can often be automatically relieved. Therefore, observation could be used to manage ovarian cyst in infants.^[1] However, pedicle torsion of ovarian cyst or intracystic hemorrhage is often encountered among infants in clinic, which usually result in unfavorable consequence such as ovarian necrosis.^[2] In this paper, we will discuss the experience of diagnosis and treatment of ovarian cyst in infants at 3 months.

MATERIALS AND METHODS

The approval for the study was obtained from the institutional review board of the Hospital of Wuhan Medical and Health Center for Women and Children. A retrospective analysis of 20 infants who suffered from ovarian cyst and received surgical treatment in our hospital from January 2009 to December 2012 was done [as shown in Table 1]. All the patients underwent B-ultrasonic, computed tomography/

magnetic resonance imaging (CT/MRI), and tumor marker examination. According to the medical history, all these lesions were preliminarily identified as benign, while the origin cannot be determined. The measurement data are described by average.

RESULTS

Preoperative imaging examinations of seven cases indicated simple cyst [as shown in Figure 1A and B]. The inspection was achieved by laparotomy with an abdominal transverse cleavage line incision in the hypogastric region in four cases. And in the remaining three cases, the inspection was achieved by three-port laparoscopy. The selection of the surgical procedure depends mainly on the choice made by parents as well as the factors, such as size of cyst, operational space of the abdominal cavity, and the general conditions of the patients. As soon as a simple ovarian cyst was confirmed during the operation [as shown in Figure 1a and b], fenestration was conducted to drain the cyst fluid. All the seven cases were diagnosed with ovarian follicular cyst on the pathological examination [as shown in Figure 1c and d]. According to the conventional B-ultrasonic examination, at 1 month, 3 months, and

This is an open access article distributed under the terms of the Creative Commons Attribution-NonCommercial-ShareAlike 3.0 License, which allows others to remix, tweak, and build upon the work non-commercially, as long as the author is credited and the new creations are licensed under the identical terms.

For reprints contact: reprints@medknow.com

Access this article online

Quick Response Code:	Website: www.jmsjournal.net
	DOI: ****

Address for correspondence: Professor Yu Lei, Wuhan Medical and Health Center for Women and Children, Wuhan - 430016, China.
E-mail: 15871716704@163.com

Received: 15-05-2015; **Revised:** 24-05-2015; **Accepted:** 10-11-2015

1 year postoperatively, ovary on the affected side developed normally in all the seven cases.

Preoperative imaging examinations of 13 cases indicated solid cystic ingredient. For seven cases, inspections were done by making incision of abdominal transverse cleavage line in the hypogastric region. For six cases, the inspections were achieved by three-port laparoscopy. During the surgery, it was discovered that all the cysts showed pedicle torsion

with varying degrees (360°-1,080°). Ovarian necrosis was revealed in four cases [Figure 2a c, d and f]. Two cases had intracystic hemorrhage, only obsolete hematocele drained out when the cystic wall was cut open [Figure 2b and e], but no tumor constituent was found. Ovariectomy was performed in the four patients who had ovarian necrosis. As for the rest of the patients, the cystic wall was cut open, followed by embrocating with carbolic acid, alcohol, and normal saline. Without resection of the cystic wall,

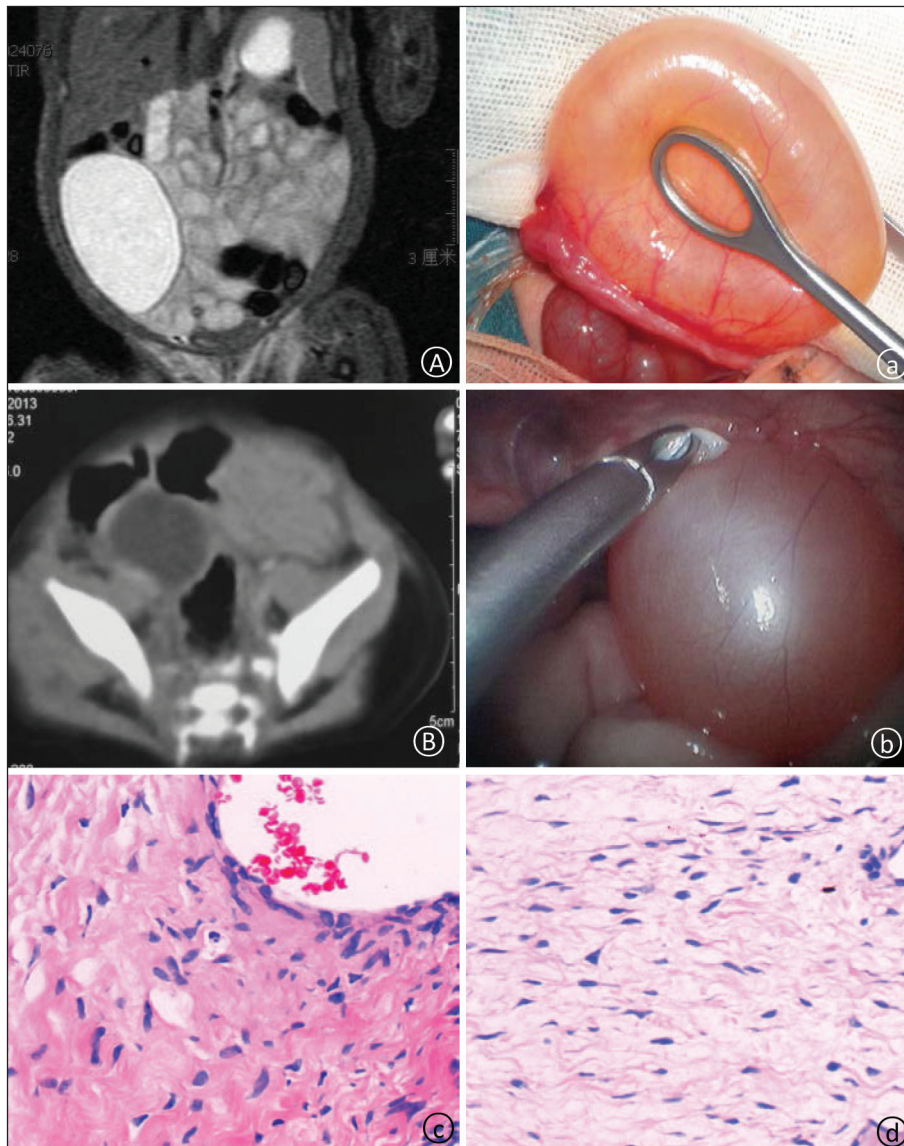


Figure 1: Preoperative MRI/CT examination indicated quasi-circular cystic low-density lump image, and it could not be distinguished from intestinal duplication and mesenteric cyst (A and B) that is proved to be an ovarian cyst during the surgery. At an early stage, laparotomy and fenestration were conducted for the cases; at the late period, the surgery was completed under trans-umbilical double-port laparoscope for the cases (a and b). The postoperative pathological result indicated simple ovarian cyst (c and d)

Table 1: Clinical datas of ovarian cyst in infants						
Ovarian cyst	No. of cases	Size (mm)	Age (days)	Laparotomy	Laparoscopy	Surgery option
Simple	7	35 (28-67)	18 (12-31)	4	3	Fenestration
Complicated	13	46 (21-89)	40 (9-90)	7	6	Enucleation
Total	20	39 (21-89)	34 (9-90)	11	9	

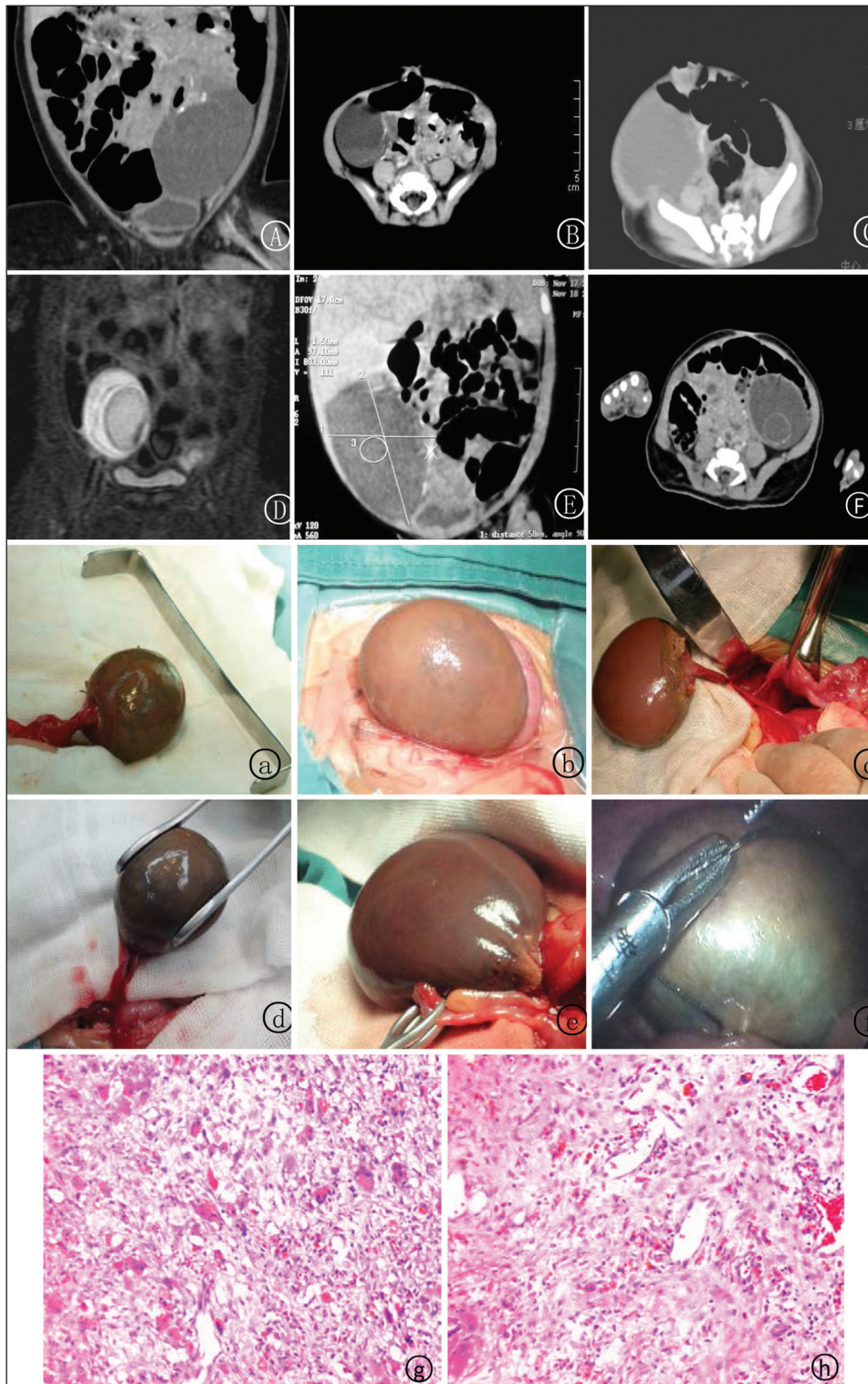

Figure 2: At the follow-up, no ovary was seen in the affected side in six cases. Preoperative MRI/CT indicated the following symptoms: Mixed ingredients in the cyst and hemorrhage (a), calcification (c, d, and f), a large number of sediments (b, d, and e), and separations in the cyst (d). This was a complicated cyst that should be distinguished from the intestinal duplication, mesenteric cyst, and teratoma. It is proved to be an ovarian cyst during the surgery. At an early stage, laparotomy and enucleation were conducted for the cases; at the late period, the surgery was performed by three-port laparoscopy technique in abdomen for the cases [Figure 1A-F]. The postoperative pathological result (2g and h) indicated ovarian cyst disease accompanied by obsolete hemorrhage, calcification, and granuloma

the ovarian tissue was retained as far as possible. As per pathological examination after the surgery, the ovarian cyst was accompanied by obsolete hemorrhage, calcification,

and granuloma [as shown in Figure 2g and h]. According to the findings of conventional B-ultrasonic examination, at 1 month, 3 months, and 1 year after the surgery, no ovary

was seen on the affected side in six cases, blood supply on the affected side was worse than that on the opposite side in two cases, and the ovary on the affected side of the other five cases developed almost normally.

During the follow-up, no ovary was seen on the affected side in six cases. According to the preoperative imaging examinations [Figure 2A-F] of the infants (MRI/CT examination), the cyst that was often accompanied by bleeding, calcification, necrosis, cyst wall thickening, and a large number of sediments and separations in the cyst was a complicated cyst. Ovarian necrosis was found in four cases [Figure 2a, c, d and f] in the surgery, and cyst bleeding appeared in two cases [Figure 2b and e].

DISCUSSION

The formation mechanism of ovarian cyst is still unknown, and most scholars consider that it originates from mature follicle.^[3,4] The difference between mature follicle and ovarian cyst lies in the size. The size of the pathological ovarian cyst is larger than 20 mm.^[5] When the mother suffers from gestational diabetes mellitus, blood poisoning, and Rhesus (RH) isoimmunization, the placenta tissue might secrete excessive β -human chorionic gonadotropin (HCG) that will result in ovarian cyst in the fetus.^[6-8] It can be discovered with prenatal ultrasound within 28-32 weeks of gestation.^[7] Most ovarian cysts can be alleviated automatically with the reduction of estrogen level after the babies are born.

The harm caused by ovarian cyst to human body is mainly triggered by complications, and the incidence rate of complications is 36-71%.^[9,10] The common complications include pedicle torsion and cyst bleeding, and necrosis of ovary and fallopian tube will be caused under severe cases. Pedicle torsion of ovarian cyst is a common complication that can occur easily to cyst larger than 50 mm. Some literature report that pedicle torsion rate of ovarian cyst is 25%.^[10] In this study, the incidence rate of ovarian cyst accompanied by pedicle torsion was 59% (13/22). This might be related to the conservative therapeutic method adopted at an early stage as well as the poor compliance of infants at the time of follow-up visit. Clinically, B-ultrasonic examination is the first choice for ovarian cyst.^[11] Once there is a possibility of torsion, MRI/CT examination is adopted. It is very important to judge the cyst nature and pedicle torsion. In this study, among the cases that lost ovary on the affected side, the following symptoms were noted on preoperative MRI/CT examination: Mixed ingredients in the cyst, hemorrhage, calcification, or necrosis. The torsional ovary is often not restored on time during the pedicle torsion and the inducement of causing ovarian torsion is not removed and these may lead to poor prognosis of ovarian

cyst. It is the most important to treatment of ovarian cyst to avoid bad consequences.

Nevertheless, most scholars consider that surgical treatment is required as long as there is a symptom,^[3,6,7,12] infants have no self-expression ability, so even pedicle torsion and ovarian necrosis can hardly be discovered. Other scholars believe that there is a possibility for ovarian cyst to be relieved automatically and the operation wound is severe, so only asymptomatic cyst larger than 40 mm or 50 mm needs surgery.^[6-8] However, an irreversible damage may occur in some cases during the observation process. In this study, the ovarian cysts of two cases that are smaller than 21 mm still underwent intracystic hemorrhage and pedicle torsion, and necrosis of the ovary was detected during surgery. The observation method was conducted in 10 infants with ovarian cyst, while no surgical treatment was performed. As a result, four cases lost ovary on one side and one case lost ovary on both sides.^[7] By contrast, fenestration was conducted in seven infants with simple ovarian cyst, which helped in avoiding severe bad consequences, such as ovarian necrosis, caused by cyst bleeding and pedicle torsion. With the development of laparoscopy in pediatric surgery, some scholars have reported successful treatment for ovarian cyst under laparoscopy.^[12,13] At the late period, this study also adopted three-port laparoscopy, and three small incisions at 3 mm and 5 mm around the navel as well as 5 mm in the hypogastric region were taken. Compared with traditional laparotomy, laparoscopic surgery has small trauma and the postoperative scar is not obvious.

Once the surgical treatment is decided for ovarian cyst, individualized treatment is selected for different types cysts. Top fenestration can be adopted for simple cyst. Seven cases of this study suffered from simple ovarian cyst, so an incision of 5 mm \times 5 mm was taken at the top for pathological examination. There are some difficulties in operation for ovarian cyst accompanied by cyst bleeding, large tumor volume, and mixed cyst fluid ingredients. In our study, puncture needle was used to puncture and suck some cyst fluids on the abdominal wall near the cyst by avoiding blood vessels on the abdominal wall under the vision of laparoscope, and then the cyst was stripped. After the cyst wall was completely stripped, there was no need to completely strip the ovary side and the ovarian tissue should be retained as far as possible, so as to avoid influence on the infant's hormone level in the future. The hemorrhagic spot was examined carefully and electric coagulation hemostasis was carried out with ultrasonic scalpel.

CONCLUSION

In conclusion, a positive intervention should be adopted for the treatment of ovarian cyst in infants, and laparoscope can be used as an effective method. Based on our results, such a

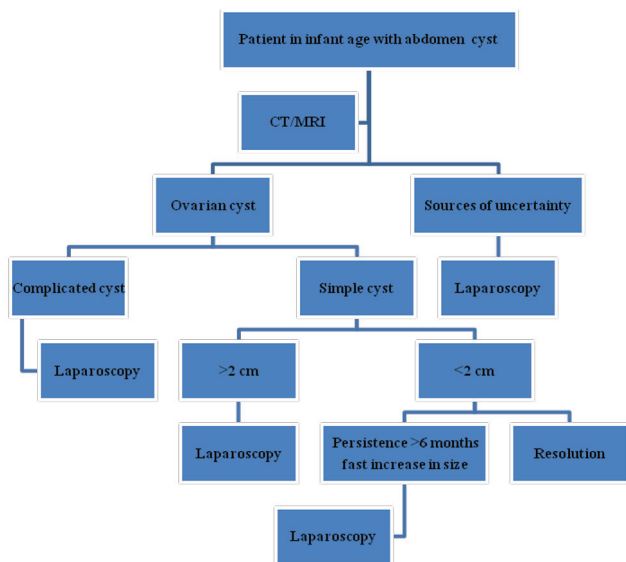


Figure 3: Algorithm for the management of ovarian cyst in infants

guideline for the management of ovarian cyst in infants is recommended [As shown in Figure 3]. This study has some shortcomings (the number of cases is less, the follow-up time is short, etc.), which we will overcome in the next research.

Acknowledgments

We thank Wang Yu-ji for his kind help in clinical datas collection.

Financial support and sponsorship

Nil.

Conflicts of interest

There are no conflicts of interest.

AUTHOR'S CONTRIBUTION

YXQ, ZNN contributed to the conception of the study. BHQ,

LW contributed significantly to analysis and manuscript preparation. YXQ, ZNN, YL performed the data analyses and wrote the manuscript. YJun, DXF, QXK helped perform the analysis with constructive discussions.

REFERENCES

1. Cuizhu F, Jidong M, Ying W, Lishuang M, Yue Z, Qinqin Y. Prenatally diagnosis, systematic management and early surgical treatment of neonatal ovarian cysts. *Chin J Neonatol* 2013;28:238-40.
2. Song G, Qimin C, Min X, Zhilong Y, Li H, Jun CA, *et al.* Torsion of ovarian cysts in neonates. *Chin J Pediatr Surg* 2008;29:65-6.
3. Grumbach MM, Kaplan SL. Fetal pituitary hormones and the maturation of central nervous system of anterior pituitary function. In: Gluck L, editor. *Modern Perinatal Medicine*. Chicago: Medical Publishers Year Book; 1975. p. 247-56.
4. Richardson GS. Hormonal physiology of the ovary. In: Gold JJ, Josimovich JR, editors. *Gynecologic Endocrinology*. New York: Harper & Row; 1980. p. 123-46.
5. Giacoia GP, Wood BP. Ovarian cyst of the newborn. *Am J Dis Child* 1987;141:1005-6.
6. Vogtlander MF, Rijntjes-Jacobs EG, van den Hoonaard TL, Versteegh FG. Neonatal ovarian cysts. *Acta Paediatr* 2003;92:498-501.
7. Tessiatore P, Guanà R, Mussa A, Lonati L, Sberveglieri M, Ferrero L, *et al.* When to operate on ovarian cysts in children? *J Pediatr Endocrinol Metab* 2012;25:427-33.
8. Rutenstock EM, Saxena AK, Schwinger W, Sorantin E, Hoellwarth ME. Pediatric ovarian tumors — dilemmas in diagnosis and management. *Eur J Pediatr Surg* 2010;20:116-20.
9. Broach AN, Mansuria SM, Sanfilippo JS. Pediatric and adolescent gynecologic laparoscopy. *Clin Obstet Gynecol* 2009;52:380-9.
10. Galinier P, Carfagna L, Delsol M, Ballouhey Q, Lemasson F, Le Mandat A, *et al.* Ovarian torsion. Management and ovarian prognosis: A report of 45 cases. *J Pediatr Surg* 2009;44:1759-65.
11. Chinchure D, Ong CL, Loh AH, Rajadurai VS. Neonatal ovarian cysts: Role of sonography in diagnosing torsion. *Ann Acad Med Singapore* 2011;40:291-5.
12. Shimada T, Miura K, Gotoh H, Nakayama D, Masuzaki H. Management of prenatal ovarian cysts. *Early Hum Dev* 2008;6:417-20.
13. Seckin B, Ozdener T, Tapisiz OL, Batioğlu S. Laparoscopic treatment of ovarian cysts in adolescents and young adults. *J Pediatr Adolesc Gynecol* 2011;24:300-3.