

Results of distraction callus osteogenesis in hand and foot in Iran: A 15-year experience

Kamal Seyed Forootan, Nazila Seyed Forootan¹, Amir Hussein Lebaschi²

Departments of Hand and Microscopic Surgery and ²Plastic and Reconstructive Surgery, Fatemeh Hospital, Iran University of Medical Sciences, Tehran, Iran, ¹School of Medicine, California State University, Northridge, USA

Background: Distraction osteogenesis (DS) is currently an important technique for lengthening shortened bones of the hand and foot. Authors report their experience in applying DS for various conditions of the hand and foot using a distractor that the senior author has designed. **Materials and Methods:** Records of patients who underwent DS for hand and foot conditions in a private clinic were retrieved between January 2001 and January 2015. Data concerning distraction, outcome, and complications were recorded. **Results:** There were 17 patients, 7 males, and 10 females with a total 24 distractions. The mean length gained was 21.2 mm (1.69) and the mean total treatment time was 198.58 (15.88) days. Overall, complications occurred in 9 (37.5%) distractions. Major complications occurred in 2 (8.33%) of distractions. Minor complications occurred in 7 (29.2%) distractions. **Conclusion:** DS is an effective modality for lengthening bones of the hand and feet for both traumatic and congenital conditions. Joint stiffness/contracture is an important complication following DS of the metatarsals.

Key words: Brachymetatarsia, congenital anomaly, distraction osteogenesis, foot, hand, trauma

How to cite this article: Seyed Forootan K, Seyed Forootan N, Lebaschi AH. Results of distraction callus osteogenesis in hand and foot in Iran: A 15-year experience. *J Res Med Sci* 2015;20:454-9.

INTRODUCTION

Since its introduction by Matev in 1967, distraction osteogenesis (DS) has been used as a method of lengthening for shortened bones of the hand and foot.^[1] In amputations, reconstructive techniques also include microvascular toe-to-hand transfer. This technically demanding procedure is also capable to provide the patients with acceptable functional results.^[2] In congenital anomalies, especially in cases of brachymetacarpia or brachymetatarsia, the number of effective corrective procedures is limited, and DS could particularly be a practical option. However, there are at least two important issues regarding implementation of DS. First, DS is a protracted treatment modality; there will be no tangible results in the short-term. Second, it entails application of a foreign device on the external surface of the limb, which calls for a high level of vigilance and patient compliance. There are numerous case series on the results of DS in hand and foot conditions. In this article, the senior author reports his experience in DS using a distractor that had designed himself [Figure 1].

MATERIALS AND METHODS

Data for patients who underwent DS for hand or foot conditions in a private surgical clinic between January

2001 and January 2015 were retrieved and recorded in a dedicated data form using their operative and outpatient clinic records. The data presented in this article are anonymous, but nevertheless all patients were asked for a written permission for publication of their data included in this research. Baseline information regarding gender, age, and underlying condition was retrieved. A detailed note was made for each distraction. All patients had been operated on by the surgeon using Forootan distractor, which was designed by the senior author. The device has a much simpler structure compared to original Illizarov's device. It comprises four pins that are attached to a central bar through two pin connectors. Pin connectors are located at either end of the central bar, and each of them holds two pins and are tightened with a screw. The pins are inserted into the bone using conventional drills. The central bar has a long rotating central screw that increases the length of the device 0.5 mm per complete revolution using a simple wrench. The main advantage of this device is reduced manufacturing cost, and simple assembly and insertion. Since, all pins are in a straight line, it is rarely required to insert a Kirschner wire (K-wire). Patients can easily lengthen the device themselves.

Number of distractors inserted, the limb and the exact bone(s) involved, need for K-wire insertion or bone

Address for correspondence: Dr. Amir Hussein Lebaschi, Department of Plastic and Reconstructive Surgery, Fatemeh Hospital, Iran University of Medical Sciences, Tehran, Iran. E-mail: lebaschia@hss.edu

Received: 11-01-2015; **Revised:** 18-02-2015; **Accepted:** 23-06-2015

graft, latency period K-wire, distraction frequency and rate, consolidation time, total treatment time, gained length, and total follow-up duration were recorded.

The latency period was defined as the interval between insertion of the distractor and beginning of distraction. Distraction frequency was defined as the number of attempted distraction(s) per day. Distraction rate was defined as distraction achieved in mm/day. Consolidation time was considered as the time interval between cessation of distraction and operative removal of the distractor. Total treatment time was the time interval between distractor insertion and removal. The gained length was recorded in millimeters.

Data pertinent to function and complications were also recorded. The function was recorded qualitatively; if the patient could flex the proximal or distal joint to the last third of the normal range of motion (ROM), the function was considered good. Maximal flexion to the middle third of the ROM and limited to the initial third of the ROM were considered fair and poor, respectively.

Complications were categorized as major and minor. Major complications were callus fracture, angulation of the bone-callus complex, premature (early) consolidation, failed consolidation, loosening of the distractor pins, mechanical failure of the distractor, and incomplete corticotomy. These complications could potentially prevent the patient from achieving the desired result and lead to treatment failure. Minor complications were pin tract infection, joint contracture (requiring capsulotomy), joint stiffness (requiring physical therapy), subluxation of the joints, adverse effects on the local tendon(s), device noncompliance on the part of the patient, persistence of a bony prominence following distractor removal, and wound complications. These complications were

considered minor because they did not lead to treatment failure. The surgical site and distractor site scar were categorized as those requiring surgical revision, and those without such need.

Data were fed to IBM SPSS statistics version 19. Descriptive statistics were used to describe the data. Since, some patients received more than one distractor; analyses were carried out using the total number of distractions and not the total number of the patients. Chi-square analysis was used to investigate correlations. Student's *t*-test was used for comparing means. The significant level was set at 0.05. The results were presented as mean (standard deviation [SD]) or number (%) where applicable.

RESULTS

There were 17 patients, 7 males, and 10 females. Eleven patients had 1 distractor inserted, 5 patients had 2 distractors inserted, and 1 patient had 3 distractors inserted, with a total number of 24 distractions. The mean age of the patients at the time of distractor insertion was 21.29 ± 1.82 (SD) years (range: 8-38 years). Of all distractions, trauma was the underlying condition in 15 (62.5%) [Figure 2]; the rest belonged to congenital anomalies (9, 37.5%) [Figure 3]. Burn was the most common traumatic cause (66%). Firework explosion and crush injuries equally constituted the rest of the traumatic causes (16% each). Interestingly, all patients with congenital anomalies in this series were females with congenital brachymetatarsia [Figure 4]. There were 14 (58.3%) hand distractions and 10 (41.7%) foot distractions. Table 1 summarizes the bones that were distracted. K-wire insertion was not required in any of our distractions. Only two distractions required iliac bone graft. All patients distracted the distractors twice daily and at a rate of 1 mm/day. Table 2 summarizes distraction times and intervals.

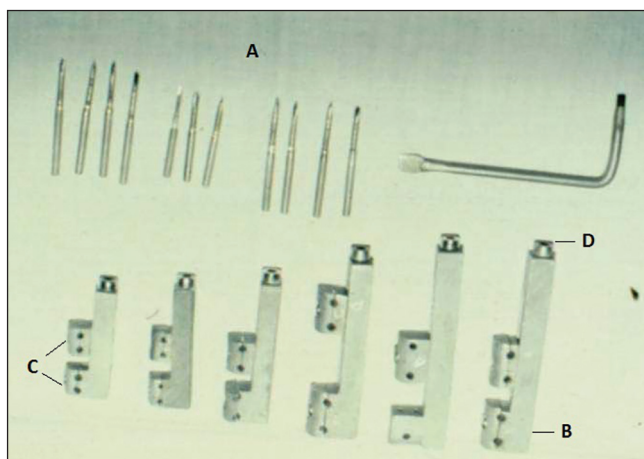


Figure 1: Forootan distractor. (a) Pins. (b) Central bar. (c) Pin connectors. (d) Central screw

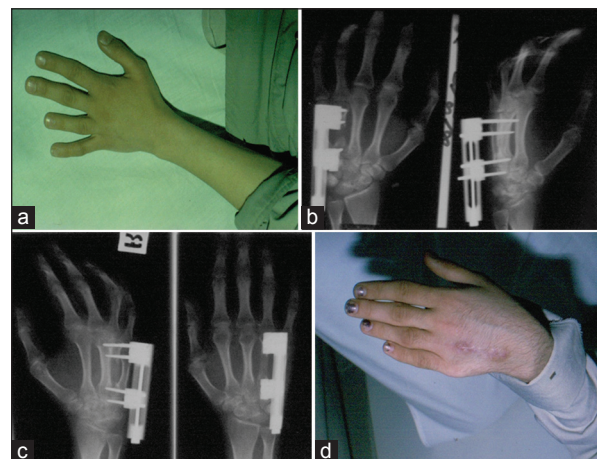


Figure 2: Distraction osteogenesis in 4th brachymetacarpia. (a) Preoperative photo. (b) Radiograph following device insertion. (c) Radiograph at the completion of the distraction. (d) Postoperative photo

The mean consolidation time was 105.81 ± 9.52 (SD) days for hand distractions and 90.40 ± 7.23 (SD) days for foot distraction ($P = 0.164$). Table 3 summarizes mean length gained by gender, limb, and underlying condition. The mean length gained was not significantly different regarding different categories of these variables. In brachymetatarsia cases, a mean length gained of 24.25 ± 2.18 (SD) mm could be achieved in these patients. The proximal joint function was good in 22 (91.7%) and fair in 1 (4.2%) distractions. Distal joint function was good in 20 (83.3%) and fair in 3 (12.5%) distractions. Overall, complications occurred in 9 (37.5%) distractions. Major complications occurred in 2 (8.33%) of distractions; 1 case of callus fracture and 1 case of device pin loosening. Callus fracture was managed by protracted treatment time. Loosening involved just one of the pins, and, therefore, the patient could complete the treatment. There were no cases of angulation, early or failed consolidation, incomplete corticotomy, and mechanical failure of the distractor. Minor complications occurred in 7 (29.2%) distractions. There were 1 pin tract infection, 4 cases of joint stiffness that required physical therapy, and two cases of joint contracture requiring capsulotomy. Joint contractures occurred only in our brachymetatarsia cases. One of the joints that incurred stiffness belonged to a male with a history of firework explosion. The remaining three joints with stiffness belonged to a female with a history of

burn in both hands. This was the only patient who received three distractors. None of the patients complained of a bony prominence.

Table 1: Frequency distribution of distracted bones

Bone	Frequency (%)
1 st metacarpal	5 (20.8)
4 th metacarpal	1 (4.2)
2 nd metatarsal	1 (4.2)
4 th metatarsal	8 (33.3)
1 st digit proximal phalanx	1 (4.2)
2 nd digit proximal phalanx	1 (4.2)
3 rd digit proximal phalanx	3 (12.5)
4 th digit proximal phalanx	3 (12.5)
5 th digit proximal phalanx	1 (4.2)
Total	24

Table 2: Distraction times and intervals among our patients

Variable	Mean \pm SD	Range
Latency period	21.09 \pm 1.68 days	16-26 days
Consolidation time	105.81 \pm 9.52 days	67-185 days
Treatment time	198.58 \pm 15.88 days	100-450 days
Length gained	21.2 \pm 1.69 mm	12-27 mm
Follow-up duration	114 \pm 10.26 months	13-156 months

SD = Standard deviation

Table 3: Mean length gained by gender, limb, and underlying condition

Variable	Mean \pm SD length gained (mm)	P
Gender		
Male	20.87 \pm 1.46	0.864
Female	21.37 \pm 1.70	
Limb		
Hand	21.14 \pm 1.47	0.332
Foot	21.3 \pm 1.27	
Underlying condition		
Traumatic	21.26 \pm 1.27	0.198
Congenital	21.11 \pm 1.47	

SD = Standard deviation

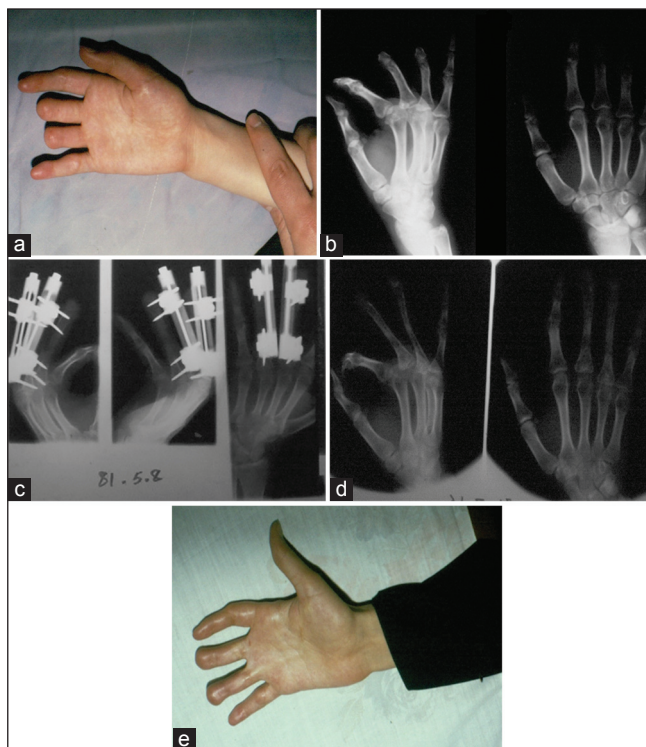


Figure 3: Distraction osteogenesis in patients with traumatic amputation of the fingers. Distraction was used for 3rd and 4th fingers bilaterally. (a) Preoperative photo of the right hand. (b) Preoperative radiograph. (c) Radiograph at the completion of the distraction. (d) Postoperative radiograph. (e) Postoperative photo of the right hand

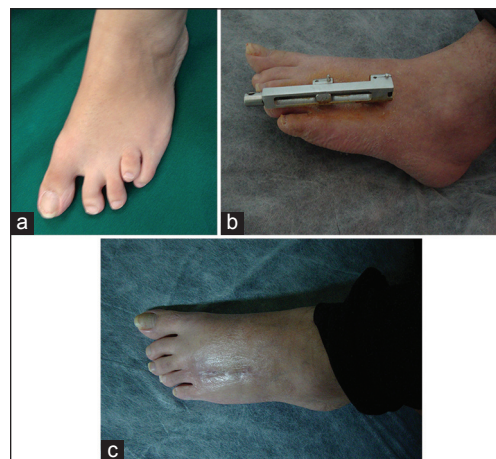


Figure 4: A female patient with 4th brachymetatarsia before, during, and after DS. (a) Preoperative photo. (b) Distractor in place with nearly completed distraction. (c) Postoperative photo

Furthermore, there was no wound complication. The occurrence of major complications showed no significant correlation with the number of distractors inserted ($P = 0.85$). The occurrence of minor complications was significantly correlated with the number of distractors inserted ($P = 0.015$). The occurrence of major and minor complications was not correlated with the underlying (traumatic or congenital) condition ($P = 0.38$ and $P = 0.61$, respectively). Three (12.5%) distraction site scars required a surgical scar revision. One distraction site scar was managed using a fractional CO₂ laser. The rest of the patients did not require any scar management initiative except for silicone gel or silicone sheet therapy.

DISCUSSION

DS in our series has produced satisfactory results; a mean length gained of 21.2 mm in <200 days. The three important features of any series of DS in hand and foot are the length gained, the treatment time, and the complications rate. The mean length gained in most series has rarely been more than an inch. The reported treatment times in different papers cover a wide range from few weeks to several months. In a series reported by Pensler *et al.*, the average period of distraction was 31.1 ± 17.6 days and the average length gained was 23.6 ± 7.3 mm.^[2] In another series, where results of the lengthening of eight traumatically shortened metacarpals or phalanges (in six patients) were reported, the mean length gained was 18.9 mm.^[3] In a comprehensive systematic review of 30 articles (424 distractions) by Kempton *et al.*, the overall mean length gained was 2.2 cm (range: 1-3.2 cm) and the mean total treatment time was 116 days (range: 36-325 days).^[4]

A principle part of any distraction protocol is the distraction chronology. It comprises several intervals that vary from study to study. These intervals include the latency period, consolidation time, and the distraction dynamics (frequency and rate). It has been the senior author's preference not to exceed a total device lengthening of 2 mm/day. In the systematic review by Kempton *et al.*, the average daily distraction length was 0.75 mm/day (range, 0.25-1.3 mm/day). Regarding consolidation time, our preferred approach had been as follows: For length gained up to 2 cm, wait for a duration roughly double the duration of device lengthening (e.g., wait 120 days for the callus to consolidate if device lengthening took 60 days); for device lengthening up to 3 cm, wait for a duration roughly three times the duration of device lengthening (e.g., wait 240 days for the callus to consolidate if device lengthening took 80 days). This consolidation time is longer than that reported in some other studies. According to Kempton *et al.*, the mean total treatment time has been 116 days (range, 36-325 days). We performed faster distraction but waited longer for the

callus to consolidate. On the whole, this approach led to longer mean total treatment time in our patients.

Overall complications rate in the systematic review by Kempton *et al.* has been as follows: There were 178 total complications in 414 distractions (42.9%), with 56% being major complications, and 44% being minor complications. Matev reported no complications in one series^[5] and a complication rate as high as 47% in another.^[6]

Most of the complications that we had in our series were minor. We had only one case of callus fracture (4.1%). Interestingly, the frequency of callus fracture according to Kempton *et al.* was reported to be 4.1%. It appears that faster distraction rate and longer duration of consolidation time had neither beneficial nor harmful effect on the risk of callus fracture in our series, although a larger number of cases are required for a conclusive report. Nevertheless, we had no occurrence of early or late consolidation. In the review by Kempton *et al.*, the rates of these two major complications have been reported 2.4% and 6.5%, respectively. Miyawaki *et al.* in their report on distraction in symbrachydactyly found that an intramedullary K-wire could maintain the alignment of the osteotomized bone.^[7]

In the review by Kempton *et al.*, longitudinal k-wires were used in eight studies (117 distractions), whereas 22 studies did not (307 distractions), with respective rates of angulation being 2.6 and 4.9%, respectively. We did not use any k-wires and did not face any significant case of angulation.

Although we had few wound complications and scar revision rates, a novel approach to callus distraction has been percutaneous or non-incisional osteotomy.^[8,9]

Nonincisional osteotomy for callus distraction in the hand and foot could possibly reduce dorsal longitudinal scarring and can achieve good cosmetic results as compared with an ordinary osteotomy involving skin incision.

DS is an excellent treatment modality for brachymetatarsia. Our cases in this series have been mainly young female patients who presented for cosmetic considerations. Joint dysfunction is important and common complication in patients undergoing DS for brachymetatarsia. In a report by Oh *et al.*, authors concluded that distraction lengthening is an effective treatment method for short fourth metatarsals, but subluxation or stiffness of the metatarsophalangeal (MTP) joint must be avoided for satisfactory results.^[10]

In another report by Song *et al.* on DS in brachymetatarsia, the average length gained was 16.5 mm (range: 13-21 mm). The authors concluded that although DS is an effective method to address fourth brachymetatarsia, and that

stiffness or subluxation of the MTP joint was not uncommon. To avoid complications that can happen as a result of excessive lengthening, authors recommended careful preoperative radiographic measurement to calculate the optimal amount of lengthening to avoid over lengthening and the complications that accompany it.^[11]

In 2007 Wilusz *et al.* published their report on DS performed on five female patients presenting with congenital fourth metatarsal shortening. Three patients (four metatarsals) were satisfied with the cosmetic and functional outcomes of their procedure. One patient was dissatisfied with the cosmetic result owing to a short digit from a short proximal phalanx, but was completely functional and resumed all of her normal activities. In this series, complications were decreased ROM, and stiffness at the MTP joint, flexion deformity of the digit, angulation of the metatarsal, prolonged distraction time due to pain, fracture of the bone callus, pin site infection, and an undesirable cosmetic appearance due to a short proximal phalanx. The authors warned that because most patients proceed with surgery for cosmetic reasons, it is important to present the possible complications, and the adjunctive surgical procedures that may be necessary for a desirable outcome.^[12]

In a much larger series, Lee *et al.* reviewed 48 patients (64 feet, 74 metatarsals) who underwent DS for the treatment of brachymetatarsia. They divided patients into two groups; the study group comprised 32 first brachymetatarsia in 19 patients (Group A) and 42 fourth brachymetatarsia in 29 patients (Group B). All patients were satisfied with the final length of the metatarsal and all had achieved bone union at the time of the last follow-up. The mean lengthening gain was 17.2 mm (42.9%) in Group A and 16.3 mm (37.3%) in Group B. The most common complication was MTP joint stiffness, which occurred in thirteen rays in Group A and in twelve rays in Group B; malalignment of the lengthened metatarsal was observed six times in each group. The authors concluded that DS for first and/or fourth brachymetatarsia provided successful lengthening of a metatarsal with eventual osseous union and was associated with similar outcomes in terms of healing index, function score, and the prevalence of complications between the two groups, although frequent complications were encountered, and no improvement in foot function was found.^[13]

In another report by Lee *et al.*, the outcome of DS for brachymetatarsia of the first metatarsal was reviewed. Average length gained was 42% (34-54). The most common complication was stiffness of the MTP joint (12 feet). Callus fractures occurred in 3 feet. The other complications were pin breakage and pin tract infection in 2 feet each. The authors pointed to the fact that DS for first brachymetatarsia can

give satisfactory cosmetic and functional results. However, several complications are commonly encountered.^[14]

LIMITATIONS

Our study is a case series and, therefore, suffers from drawbacks of such a design; there was no randomization, and, therefore, statistical inferences are of limited significance. For better assessment of our device application and outcome, a larger number of patients are required. A small fraction of patients that come to our office looking for lengthening operations are a good candidate for DS since, it is a lengthy procedure that calls for high levels of patients' compliance and cooperation. Therefore, it is not easy to collect data for such a treatment plan on a large number of patients with various conditions.

Our results imply that DS is an effective and relatively safe procedure for lengthening bones of the hand and feet. We have used relatively faster distraction rate and longer consolidation time and witnessed few complications, especially those that involve the developing callus. We might as well turn to shorter consolidation times to see if comparable complication rate could be achieved.

ACKNOWLEDGMENTS

Authors would like to thank the operating room staff at Azar Surgical Center, Tehran, Iran.

AUTHOR'S CONTRIBUTION

KSF contributed to the conception of the work, conducting the study, revising the draft, approval of the final version of the manuscript, and agreed for all aspects of the work. NSF contributed in the conception of the work, revising the draft, approval of the final version of the manuscript, and agreed for all aspects of the work. AHL contributed to the conception of the work, conducting the study, revising the draft, approval of the final version of the manuscript, and agreed for all aspects of the work. PM contributed in the conception of the work, drafting and revising the draft, approval of the final version of the manuscript.

REFERENCES

1. Matev I. A new method of thumb reconstruction. Paper presented at: Anglo-Scandinavian Symposium of Hand Surgery; May, 26-27. Lausanne, Switzerland: Lausanne; 1967.
2. Pensler JM, Carroll NC, Cheng LF. Distraction osteogenesis in the hand. *Plast Reconstr Surg* 1998;102:92-5.
3. Hosny GA, Kandel WA. Distraction lengthening by callotaxis of traumatically shortened bones of the hand. *J Trauma Acute Care Surg* 2012;72:1676-80.
4. Kempton SJ, McCarthy JE, Afifi AM. A systematic review of distraction osteogenesis in hand surgery: What are the benefits,

- complication rates, and duration of treatment? *Plast Reconstr Surg* 2014;133:1120-30.
5. Matev IB. Thumb reconstruction in children through metacarpal lengthening. *Plast Reconstr Surg* 1979;64:665-9.
 6. Matev IB. Thumb reconstruction through metacarpal bone lengthening. *J Hand Surg Am* 1980;5:482-7.
 7. Miyawaki T, Masuzawa G, Hirakawa M, Kurihara K. Bone-lengthening for symbrachydactyly of the hand with the technique of callus distraction. *J Bone Joint Surg Am* 2002;84-A:986-91.
 8. Arata J, Morimoto N, Soeda H, Kometani A, Abe S, Suzuki S. Nonincisional osteotomy for gradual lengthening by callus distraction in the hand and foot. *Ann Plast Surg* 2011;67:232-4.
 9. Volpi AD, Fragomen AT. Percutaneous distraction lengthening in brachymetacarpia. *Orthopedics* 2011;34:e424-7.
 10. Oh CW, Sharma R, Song HR, Koo KH, Kyung HS, Park BC. Complications of distraction osteogenesis in short fourth metatarsals. *J Pediatr Orthop* 2003;23:484-7.
 11. Song HR, Oh CW, Kyung HS, Kim SJ, Guille JT, Lee SM, *et al.* Fourth brachymetatarsia treated with distraction osteogenesis. *Foot Ankle Int* 2003;24:706-11.
 12. Wilusz PM, Van P, Pupp GR. Complications associated with distraction osteogenesis for the correction of brachymetatarsia: A review of five procedures. *J Am Podiatr Med Assoc* 2007;97: 189-94.
 13. Lee KB, Park HW, Chung JY, Moon ES, Jung ST, Seon JK. Comparison of the outcomes of distraction osteogenesis for first and fourth brachymetatarsia. *J Bone Joint Surg Am* 2010;92: 2709-18.
 14. Lee KB, Yang HK, Chung JY, Moon ES, Jung ST. How to avoid complications of distraction osteogenesis for first brachymetatarsia. *Acta Orthop* 2009;80:220-5.

Source of Support: Nil, **Conflicts of Interest:** No conflict of interests.